

Malignant Melanoma in a Spectacled (Bronze-winged) Duck (*Specularnas specularis*)

Caron Baugher, NC State University College of Veterinary Medicine, Raleigh, NC
Dr. Oscar Fletcher DVM, PhD, NC State University College of Veterinary Medicine, Raleigh, NC
Dr. John Barnes DVM, PhD, NC State University College of Veterinary Medicine, Raleigh, NC

MALIGNANT MELANOMA

- Malignant melanomas are common in dogs and grey horses - rare in birds
- Causes include mutations in DNA due to genetic and environmental factors such as exposure to UVA and UVB light
- Reported cases in birds: African Grey Parrots (2) Budgerigar (1) Penguins (2)
Raptors (3) Merlin (1) Ducks (7)

CASE HISTORY

- A female Spectacled (Bronze-winged) Duck (*Specularnas specularis*) approximately 10 – 12 years of age was presented for necropsy following euthanasia
- Severe sinusitis was suspected, no dyspnea
- Last clutch of infertile eggs laid in 2004
- Large mass located on the right side of the face

DISCUSSION

- Gross necropsy findings included a large, irregular mass filled with a dense black substance located in the right infraorbital sinus causing proptosis (Fig. 1, 2, 3, 4)
- The mass had advanced rostrally to the right lateral beak and caudally to encircle the brain and cranial cervical muscles (Fig. 5, 6)
- A second, irregular black mass was found in the region of the thyroid at the thoracic inlet
- No metastasis to other organs was identified (Fig. 7)
- Histological examination showed a black tumor that consisted of an infiltrative growth of melanin-containing neoplastic cells (Fig. 8)
- The neoplasia had invaded the dermis causing caseous necrosis and leaving very little normal tissue (Fig. 9)
- The markedly atypical cells contained areas of uniformly granular pigment as well as globular shaped areas of varying sizes (Fig. 10)

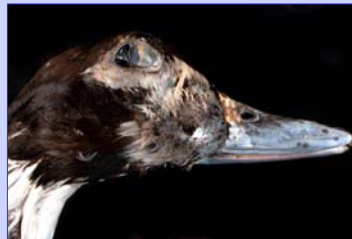

Figure 1

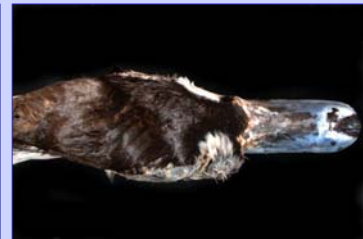

Figure 2



Figure 3



Figure 4

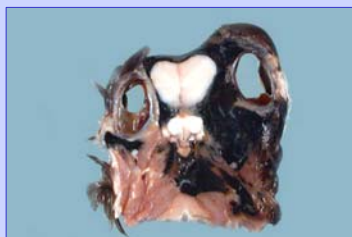


Figure 5

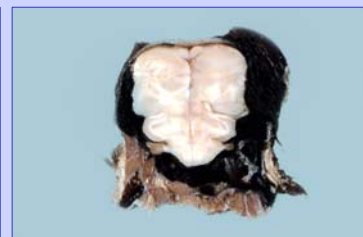

Figure 6

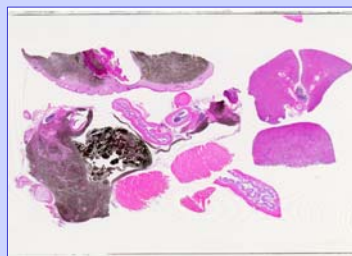


Figure 7

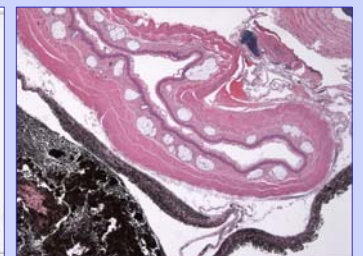


Figure 8

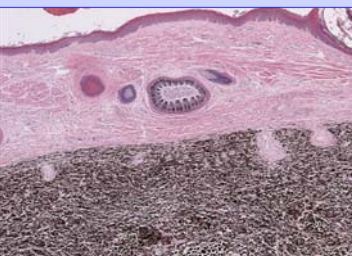


Figure 9

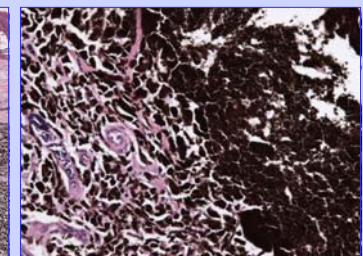


Figure 10