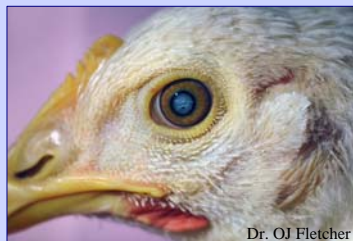
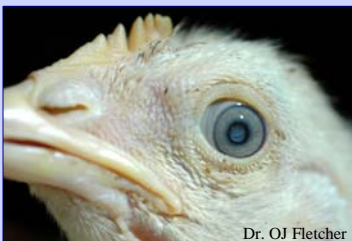
# Cataracts of Unknown Etiology in Broiler Breeders

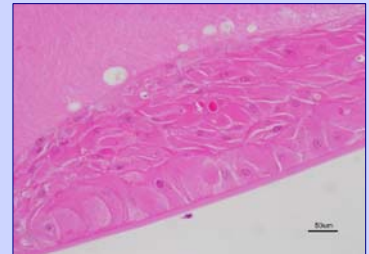
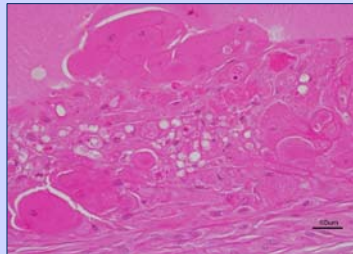
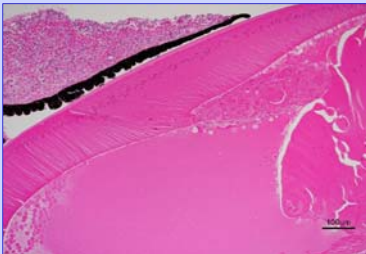
Marie Deavers and Dr. H. John Barnes  
NC State University, College of Veterinary Medicine, Raleigh NC

## Broiler Breeders

- 19 Flocks were affected over a 4 year period of time
- Hens primarily affected
- The age of affected birds varied from 8 weeks to 56 weeks
- Two different breeds were affected



## Histological Findings



- Anterior uveitis - lymphocytic iridocyclitis
- Vacuolization and proliferation of lens epithelium
- Widespread posterior cortical bladder cells
- Focal anterior capsular lens proliferation
- Extensive liquefaction

## Conclusion

- Etiology is unknown
- Further studies are being planned