

Cervical Ganglioneuroma with Epithelial Differentiation in an African Grey Parrot (*Psittacus erithacus*)

Michelle Diener, Keith Linder¹ DVM, PhD, Keven Flammer² DVM, Laurel Degernes DVM and John Barnes¹ DVM, PhD

¹Dept. of Population Health and Pathobiology and ²Dept. of Clinical Sciences, North Carolina State University, College of Veterinary Medicine, Raleigh, North Carolina, 27606

Case History

An adult male African Grey parrot presented with a large cervical mass caudal to the mandible. An ultrasound showed the mass to be highly vascular, solid, and encapsulated. Within 5 weeks the mass had enlarged by 25%. A neoplasm was suspected due to the morphology and rapid growth; the mass was surgically removed for histopathological diagnosis.

Gross Pathology

- Subcutaneous location, anterior cervical region
- Soft tissue mass, irregularly spherical and expansile
- Size = 54 x 51 x 40 mm, weight = 82 grams

Histopathology

- Well-demarcated, encapsulated, non-invasive
- Heterogeneous neoplastic cell population and fibrovascular trabeculae (**Fig. 1**)
- Epithelial differentiation (Squamous type) (**Fig. 2**) and neuronal differentiation (ganglion cells) (**Fig. 3**)

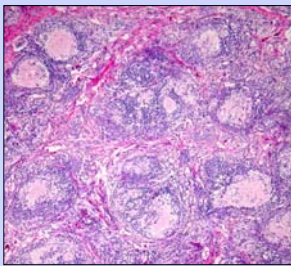


Figure 1 Heterogenous islands of neoplastic cells separated by fibrovascular trabeculae (Hematoxylin-eosin stain, Mag. 40x)

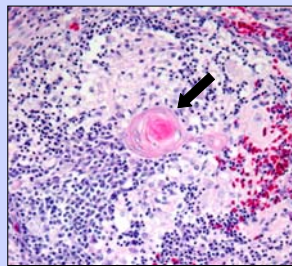


Figure 2 Discrete epithelial foci with a central laminated keratin "pearl" (arrow). (Hematoxylin-eosin stain, Mag. 200x)

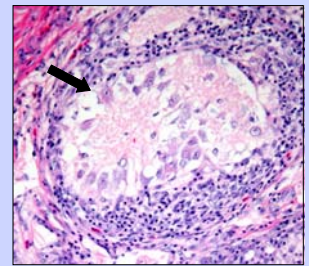


Figure 3 Central large polygonal ganglion cells (arrow) in a loose fibrillar stroma. (Hematoxylin-eosin stain, Mag. 200x)

Immunohistochemistry Results

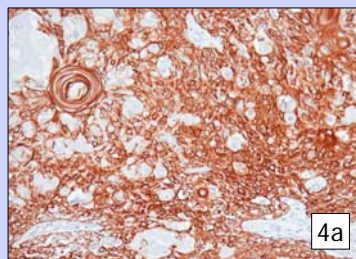
Immunohistochemistry (IHC) was performed (**Table 1**) to characterize the heterogenous cell populations in the neoplasm and to confirm the neural and epithelial patterns of differentiation. Strong cytokeratin staining (**Fig. 4a**) confirmed epithelial differentiation. Vimentin staining predominately involved support stroma and scattered neoplastic cells (**Fig. 4b**). Strong neural specific enolase (NSE) (**Fig 4c and 4d**) and scattered S-100 staining confirmed neuronal differentiation.

TABLE 1: Summary of immunohistochemical staining results for the anterior cervical mass from a African Gray Parrot

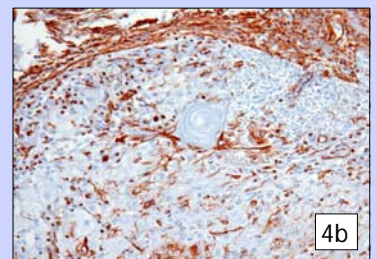
Stain	Staining Intensity*	Staining Pattern
NSE	+++	Ganglion cells and central fibrillar stroma
Cytokeratin	+++	Primitive epithelium and keratin pearls
Vimentin	++**	Marginal support cells and scattered dendritic cells in fibrillar stroma
S-100	+	Ganglion cells, scattered stromal cells, and fibrovascular trabeculae stained weak positive

* Staining of neoplastic cells

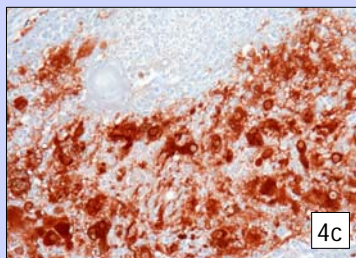
** Strong staining of non-neoplastic fibrovascular stroma also observed



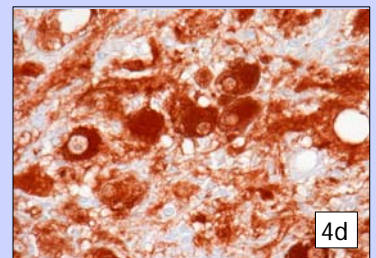
4a



4b



4c



4d

Figure 4 Cervical mass, representative immunohistochemical staining results for Cytokeratin (4a), Vimentin (4b), NSE (4c & d); avidin-biotin-peroxidase complex technique and diaminobenzidine tetrahydrochloride.

Summary

- A diagnosis of **ganglioneuroma** is based on the presence of ganglion cells and immunohistochemical evidence of neural differentiation
- Ganglioneuromas are well-differentiated benign tumors of the sympathetic nervous system, which is consistent with the behavior of this neoplasm
- Epithelial differentiation is an uncommon feature of ganglioneuromas
- This is the first report of a ganglioneuroma in a psittacine